

Case Study

Reduction in Symptoms Associated with Parkinson's Disease Subsequent to Subluxation-Based Chiropractic Care: A Case Study

Matthew Norton, D.C.¹
Megan Callanan, D.C.²

1. Private Practice of Chiropractic, Fresno, CA
2. Private Practice of Chiropractic, Atlanta, GA

Abstract

Objective: The purpose of this case study is to provide a detailed report on the symptomatic improvement of a patient with Parkinson's disease (PD) undergoing Activator Methods chiropractic care.

Clinical Features: A 68 year-old female, diagnosed with Parkinson's disease four months prior, presented to a private practice for chiropractic care. She began experiencing symptomatic complaints of essential tremors one-year prior to being diagnosed with Parkinson's disease. Her symptoms, which seemed to be progressively worsening, included resting tremors in her hands, fatigue, lack of motion in the cervical and lumbar spine with associated neck pain/stiffness and lower back pain.

Interventions and Outcome: Over a four-month period, the patient was seen twice per week during which she was evaluated and adjusted using the Activator protocol. In addition, postural exercises were performed by the patient for the cervical spine in order to improve range of motion and mobility of the neck. Improvements in ranges of motion, paraspinal thermography and sEMG were noted along with the patient's subjective report of improvements in tremors, fatigue, mobility, rigidity and neck pain/stiffness and lower back pain following Activator adjustment.

Conclusion: Spinal subluxation may be a contributing factor in the symptomatic expression of Parkinson's disease. Reduction in subluxation with Activator analysis and adjustment may be an effective approach for managing the symptoms associated with PD; however more research is warranted investigating the effects of Activator Methods Chiropractic Technique (AMCT) and Parkinson's disease.

Key Words: Parkinson's disease. tremors. AMCT. subluxation. chiropractic

Introduction

Parkinson's disease (PD) is a progressive neurodegenerative disease due to dopaminergic neuron degeneration within the Substantia Nigra.¹ According to the Parkinson's Disease Foundation, as many as one million Americans live with Parkinson's disease and approximately sixty thousand are diagnosed with PD each year.² Although there are a number of treatment options available for the symptoms that accompany PD, there is currently no known cure.

Parkinson's disease is often characterized by both motor and non-motor (cognitive and limbic) deficits. The motor

abnormalities associated with PD often include hypokinetic signs such as akinesia/bradykinesia, rigidity and loss of normal postural reflexes, as well as hyperkinetic symptoms such as essential and resting tremors. Dopamine depletion in the striatum is the hallmark of PD, however the exact pathophysiology of Parkinson's symptoms, specifically the tremors associated with PD, is still under debate.³

Aside from the hypokinetic signs of Parkinson's disease, the classic Parkinsonian tremor is defined as a resting tremor, a tremor that occurs in a body part that is not voluntarily activated and is completely supported by gravity.⁴ For the most part, resting tremors are inhibited during movement and

may reoccur with the same frequency when adopting a certain posture or during movement.⁵ Also experienced by those with PD, are essential tremors, or action tremors. Action tremors can be further divided into postural or kinetic tremors, which typically occur during voluntary movement.⁴ The upper limbs are affected in approximately 95% of tremor patients, followed by head (34%), lower limbs (20%), voice (12%), face and trunk (5%).⁶

As previously stated, patients with PD often suffer from akinesia/bradykinesia in addition to resting tremors. Therefore, it is imperative that when the presence of a tremor is detected, the patient's gait is also analyzed due to the fact that the patient can exhibit difficulty with gait initiation, reduced arm swing and freezing.⁴ The abnormal gait pattern seen in PD predisposes the patient to falls, with the incidence of falling being between 40%-70%.^{7,8} Increased falling, abnormal posture and decreased mobility may cause both acute and chronic musculoskeletal problems contributing to the bone and joint problems seen in Parkinson's disease.⁹ The postural abnormalities associated with Parkinson's disease are those affecting the components of orientation and stabilization.

Affected individuals typically present with bent spinal posture associated with lenticular lesions, suggesting the basal ganglia plays a crucial role in maintaining axial posture. Common postural deficits may include extreme neck flexion (antecollis), Pisa syndrome and camptocormia. Pisa syndrome is a truncal deformity characterized by trunk tilting in the lateral plane, while camptocormia involves abnormal posture of the trunk in the anteroposterior plane with marked flexion of the thoracolumbar spine.¹⁰ Furthermore, Schenkman et al. observed a marked decrease in range of motion (ROM) when patients with PD performed tasks involving longitudinal spinal rotation while seated performing a reaching task, thus concluding that spinal ROM is impaired in the early stages of Parkinson's disease.¹¹ The aforementioned postural irregularities may be due in part to altered proprioceptive activity.¹²

Given that Parkinson's disease is primarily a degenerative neurological disorder, as the patient ages and the disease advances, the patient's quality of life declines, especially for those who experience tremors associated with the disease.¹³ Currently there is no cure for PD; therefore, current medicinal and surgical therapies only provide temporary relief of symptoms.

The most commonly prescribed pharmaceutical treatment is Levodopa (L-dopa), which acts as a synthetic precursor to Dopamine. L-Dopa is often combined with Carbidopa to form Sinemet, which prevents the nausea and vomiting that occurs when Levodopa is taken alone and also allows for more of L-Dopa to be converted in the brain rather than in the bloodstream. Unfortunately, with prolonged use of Levodopa, patients may experience dyskinesias and "on-off" periods where the medication spontaneously starts/stops working, causing dopamine agonists to also be utilized as pharmacological treatment.

Dopamine agonists such as Mirapex or Requip are drugs that stimulate the parts of the human brain influenced by

dopamine. In essence, the brain is tricked into thinking it is receiving the dopamine it needs. Generally, dopamine agonists are not as potent as Carbidopa/Levodopa, and therefore are less likely to cause dyskinesias. As with any pharmaceutical, dopamine agonists also have side effects including nausea, hallucinations, sedation, lightheadedness due to low blood pressure, and even addictive behaviors.²

The most common surgical intervention used in the treatment of PD today is deep brain stimulation (DBS). Deep brain stimulation involves the implantation of electrodes into a targeted brain area with the use of magnetic resonance imaging (MRI) and neurophysiological mapping. A device called an impulse generator or IPG (similar to a pacemaker), is implanted under the collarbone to provide an electrical impulse to a part of the brain involved in motor function. DBS is not a cure for Parkinson's disease and does not slow the progression of the pathology; however, it has been seen to be extremely effective for those patients who experience disabling tremors, wearing-off spells and medication-induced dyskinesia.²

Case Report

Clinical Features

A 68-year old female presented to a private chiropractic practice with Parkinson's disease, neck stiffness/pain radiating into the left arm and low back pain which began three years prior, when the patient was involved in a motor vehicle accident. The patient was travelling in a car going approximately 10 miles per hour (mph) while decelerating, when the vehicle was rear-ended by a car travelling roughly 65 mph. The patient stated that since the accident occurred, the neck stiffness/pain and low back pain had been constant.

The patient's primary complaint of Parkinson's disease was first detected in November, 2009 when the patient began experiencing essential tremors, and it was not until one year later, the patient was diagnosed with early-stage Parkinson's disease. The patient relayed that her complaints interfered with her work, sleep and daily routine. Sleeping for an extended period of time in one position aggravated her condition. The patient noted that she had seen other doctors for her current conditions, consisting of a medical doctor (neurologist), chiropractor, massage therapist and physical therapist. Parts of her medical history were significant with the subjective findings she was presenting with which she was presenting.

The patient noted that the only accident/injuries she had suffered were those from the MVA occurring in 2008. Surgeries the patient had undergone included a benign lumpectomy in 1992 and a tonsillectomy/adenoidectomy in 1948. The patient relayed the only medication she was taking was Sinemet for the treatment of symptoms associated with PD and vitamins. The remainder of the patient's medical history was unremarkable, other than the patient currently suffers from hay fever.

Examination

In addition to a standard clinical history, the physical examination performed on the patient included range of motion, functional leg length testing, gait analysis, thermography and surface electromyography (sEMG). Palpation of trigger points and tender nodules was also performed. Visual observation showed a bilateral resting and essential tremor of the hands, bradykinesia of the upper and lower extremities and rigidity of the neck.

Active range of motion (ROM) testing is used in chiropractic clinical practice in order to measure movement of the spine as an outcome measure or determine diagnosis, disability and treatment effects. There are various methods of assessing active ROM such as visual examination, inclinometry, radiographs, etc.¹⁴ In a study conducted regarding the intra-instrument reliability of four goniometers, it was found that the bubble goniometer (the instrument used to measure active ROM in this case) was as reliable as the electric goniometer in measuring cervical spine ranges of motion among males and females.¹⁴

Spinal range of motion examination revealed significant restriction in cervical flexion and extension (30°), right rotation (35°), left rotation (40°), right and left lateral flexion (5°). Lumbar flexion (50°), extension (5°), right lateral flexion (6°) and left lateral flexion (2°) were also significantly diminished (Table 1). In addition to decreased ranges of motion, the patient also experienced pain when turning her head to the right and left.

<i>Range of Motion (degrees)</i>			
	2/14/11	4/20/11	6/13/11
Cervical			
Flexion	30	30	33
Extension	30	40	41
Right Lateral Flexion	5	20	22
Left Lateral Flexion	5	14	23
Right Rotation	35	40	49
Left Rotation	40	39	41
Lumbar			
Flexion	50	68	78
Extension	5	12	13
Right Lateral Flexion	6	6	11
Left Lateral Flexion	2	8	13

Table 1. Range of Motion

Functional leg length assessment is utilized in a number of chiropractic techniques as a method of analysis regarding the general health of the nervous system. The “functional short leg” can serve as both an indicator of subluxation and as an outcome measure, thus deriving treatment strategies based on leg-check findings.¹⁵ As evidenced by various research efforts, the functional leg length assessment has been evidenced to have high degrees of inter and intra-examiner reliability as well as validity as an analytical tool.¹⁶

The functional leg length test performed on the patient, revealed a significant left leg length discrepancy of greater than one inch.

Upon observing the patient’s gait, eversion of the left foot was noted. Soft tissue palpation of the spine revealed tightness the

in left lumbar spine, tightness at C2, C3, C5 on the right side and at C5 on the left side. Severe hypertonicity of the trapezius muscles was indicated bilaterally.

Thermal scanning was used to assess paraspinal muscle heat asymmetry and muscle tone. Thermography is used as a diagnostic tool to assess the skin temperature of paraspinally as a way to assess the functionality of the autonomic nervous system. According to Uematsu et al, “The skin, one of the largest organs of the body, is equipped with a network of vessels accompanied by dense nerve fibers. It serves as the body’s thermoregulator, controlling blood flow within a few millimeters of the body surface. The system is governed by autonomic nerve impulses generated from the hypothalamus and the brain as a whole. The system is both anatomically and physiologically symmetrical.”¹⁷

In a study conducted by Uematsu et al, it was concluded that the degrees of thermal asymmetry found when conducting a thermography scan can be used as a standard in the assessment of sympathetic nerve function and furthermore, the degree of asymmetry can be used as a quantifiable indicator of dysfunction within the spine.¹⁷

The thermography scan performed on the patient, indicated thermal asymmetries throughout the spine with the greatest difference located at T2 on the left side, a moderate asymmetry that is two standard deviations from normal (Figure 1). In addition to thermography, static surface electromyography was also performed.

Electromyography (EMG) is the process of collecting and recording the electrical potentials associated with muscular activity, while surface electromyographic (sEMG) scanning employs hand-held electrodes which are placed on the skin overlying the muscle tissue being evaluated. When the signal stabilizes, a computer records it and the electrodes are then moved to the next anatomical site. In practice, paired sets of electrodes are placed simultaneously at varying numbers of corresponding contralateral paraspinal sites along the length of the spine.¹⁸ Static surface electromyography is often used to determine asymmetrical muscle contraction, abnormal muscle recruitment patterns, and assess muscle tone.^{18,19}

The sEMG scan performed on the patient indicated hypertonic musculature in the thoracic and cervical regions, with the greatest hypertonicity located at C4 bilaterally. At C4, the patient had 18.0 microvolts of electrical activity on the right side and 19.0 microvolts on the left side (Figure 1). This reading indicates that the musculature at C4 is severely hypertonic.

Given the results of the physical exam, enough data was warranted to proceed with the diagnostic portion of the exam. A lateral cervical radiograph was taken in order to determine the presence of pathology or contraindication to chiropractic treatment. Radiographic diagnosis revealed a reversal of the cervical curve, decreased disc space at C4/C5 and C5/C6 with moderate degenerative joint disease (DJD) and severe disc space narrowing at C6/C7 with severe DJD and intervertebral osteochondrosis (IVOC). All other osseous and soft tissue structures on the radiograph were unremarkable (Figure 2).

Intervention

Upon completion of the initial chiropractic examination, findings were assessed using Activator protocol and a patient management plan was established in order to begin care. The patient was seen twice per week initially for sixty days. After sixty days had passed, the patient was re-examined and any necessary adjustments to the care plan were made.

The patient received chiropractic adjustments using the Activator Methods Chiropractic Technique (AMCT). The theories behind AMCT evaluation methods include the articular dysfunctions believed to mediate various health problems. These dysfunctions have been termed the “subluxation complex,” a component of the broader “subluxation syndrome.”²⁰ The AMCT analysis is based on the assumption that faulty biomechanical behavior of articulations is reflected in differences and changes in leg lengths. The assessment protocol prescribes a series of prone leg-length observations and provocative tests to evaluate the functions of joints from the feet to the cervical spine. It is believed that dysfunction of more caudal segments must be removed before more rostral structures can be evaluated.²¹

The assessment involves repeated systematic observations of relative leg lengths (legs extended or “position 1”) and apparent changes in the leg lengths (flexed knee or “position 2”) while the patient lies prone. These observations are made prior to and after a series of provocative maneuvers including isolation testing, pressure testing, stress tests and adjustments are performed.²¹

“Isolation tests” are maneuvers performed by the patient to stimulate subtle muscular changes in the body by way of mechanoreceptors in muscle, diarthrodial joints, ligaments and tendons associated with the axial and appendicular skeletons. In the presence of articular dysfunction, specific movements in combinations of rotation, flexion-extension, and abduction-adduction are thought to provoke specific neuromuscular irritation and contractions, which manifest in leg-length changes. The reaction of the initially shorter leg in position 1 is believed to indicate the presence or absence of subluxation within the body.^{22,23}

“Stress tests” are applied by the doctor’s forefinger to accentuate the suspected dysfunction or subluxation, as indicated by the leg length inequality test. The force is applied in the direction of the subluxation. If no change in apparent leg length is noted, the target area is considered to be free of dysfunction; further shortening of the initial short leg in position 1 is considered an indicator of subluxation.²¹

Contradictory to “stress tests”, “pressure tests” involve digital force applied to the suspected area of subluxation in the direction of correction. The vector is applied to temporarily reduce the positional misalignment of a vertebral joint. With a pressure test, the leg-length inequality test is expected to balance.²⁴

In order to determine the inter-examiner reliability of leg-length analysis using AMCT, Fuhr and Osterbauer used Activator 4 instruments to examine the leg lengths of 30 other Activator instructors. They found marginal to excellent concordance beyond chance for trichotomous observations

(left short, right short, or even) and weaker interobserver coefficients of agreement for recording the differences between right versus left heel-sole interfaces. Weaknesses in this study were found however, regarding a lack of randomization of the order of examiners and the vocal report of the short-leg side in the presence of subjects.²⁵

During the first sixty days of treatment, the patient presented with multiple subluxations of the cervical, thoracic and lumbar spine as well as the pelvis. On almost every visit during the initial phase of care, the patient had subluxations at C2, T3/T4, L3/L4, and either an anterior-superior (AS) or posterior-inferior (PI) misalignment of the ilium. All subluxations found were detected using leg-length inequality paired with isolation, pressure and stress tests. Once the misaligned segments were found, adjustments using the Activator were administered.

The Activator instrument is used as an alternative to manual adjustment, delivering the same adjustment with less force, yet still achieving the same amount of vertebral movement. In 2000, a study was conducted to determine the amount of pressure needed to produce movement of the vertebrae in the lumbar spine. It was determined that a manual thrust exerting 540 N of force on L4 caused the L4/L5 vertebral unit to move 1.3 millimeters.²⁶ A similar study was conducted in 1994, where it was found that 140 N of force delivered by an Activator thrust on T11, T12, L1, L2 and L3 caused L3/L4 and L4/5 to move 0.3-1.6 mm.²⁷ These studies highlight the principle that adjustments can be delivered with less force, yet still achieve the same amount of vertebral movement within the spine.

In the case of this patient, the Activator was the best method of delivering the adjustment given her state of health and the degeneration present in her cervical spine. Adjustments of the spine, specifically the upper cervical spine, have been shown to improve symptoms in patients with PD, including a reduction in tremors, hypertonicity of upper and lower limb muscles, increased energy and a reduction in postural abnormalities.²⁸⁻³¹

In addition to chiropractic adjustments, the patient was also given postural exercises for the cervical spine. The goal of the exercises given was to increase the range of motion in the patient’s cervical spine as well as to decrease the tension within the paraspinal muscles, allowing the patient to have enhanced neck mobility.

Outcome

The patient was adjusted a total of eleven times during the course of the sixty day treatment plan. The patient was evaluated using the Activator protocol and adjusted with the Activator instrument. As previously stated, the patient was also performing exercises for the cervical spine in conjunction with adjustments in order to increase ranges of motion and overall mobility of the cervical spine.

Upon re-examination, the patient reported significant changes in her symptomatology. The patient noted a decrease in hand tremors and improved flexibility in her cervical spine. In addition, she confirmed a reduction in lower back pain and an

increase in energy levels. There was no alteration of her use of Sinemet during those six weeks.

Although the patient had begun using Sinemet in order to treat the motor symptoms she was experiencing, she did relay that she noticed a decrease in the frequency of tremors prior to beginning the medication. The patient's concurrent treatments utilizing prescription drugs and chiropractic care may be a limitation of the study; however, do not negate the effectiveness of chiropractic in reducing the motor symptoms associated with PD.

Re-measurement of the patient's ranges of motion revealed significant improvements in cervical extension (40°), right lateral flexion (20°), left lateral flexion (14°) and right rotation (40°). Lumbar ranges of motion were also increased with considerable changes in flexion (68°), extension (12°) and left lateral flexion (8°) (Table 1). All remaining ranges of motion were consistent with the original measurements or were only slightly improved.

A follow-up scan measuring thermography and static surface electromyography was performed, indicating a reduction in thermal asymmetry as well as muscle hypertonicity within the patient's spine. All of the heat asymmetries found were mild in nature (one standard deviation from normal) with the greatest asymmetry located at L4 on the right side. In regards to the sEMG, a dramatic reduction in muscle tone occurred in the cervical spine as well as the lower thoracic spine (Figure 3).

Re-examination findings concluded the patient was responding to care and experiencing significant gains in spinal, physical and mental health. The patient's management plan remained the same consisting of chiropractic adjustments twice per week for sixty days with a re-examination at the conclusion of the treatment plan to determine patient's progress toward correction.

The patient again underwent a total of eleven adjustments over the sixty-day treatment period. The patient continued to be evaluated using the Activator protocol and adjusted with the Activator instrument. Similar to the first treatment period, subluxations were found at C2, T3/T4, L3/L4/L5, and either an AS or PI misalignment of the ilium was detected. All subluxations found were detected using leg-length inequality paired with isolation, pressure and stress tests. She continued performing exercises for the cervical spine in conjunction with adjustments in order to increase ranges of motion and overall mobility of the cervical spine.

Upon re-assessment, the patient noted continued improvements in original symptomatology. Since beginning care, she stated improved neck rotation as well as a continued reduction in hand tremors. Additionally, the patient stated that she felt less strain on her lower back.

Follow-up measurements of the patient's ranges of motion indicated a further increase in cervical flexion (33°) and left lateral flexion (23°). Increases in lumbar range of motion also occurred with significant improvement in flexion (78°), right lateral flexion (11°) and left lateral flexion (13°). The

remaining ranges of motion unmentioned either remained the same or were slightly improved (Table 1).

Scans measuring thermography and sEMG were again conducted to continue assessing the patient's progress since the initiation of treatment. Thermography scans showed improvement with thermal asymmetries occurring in only six vertebral segments ranging from mild to moderate (two standard deviations from normal) in nature, with the greatest asymmetry occurring at C6 on the right side (Figure 4).

All of these findings were consistent with a positive patient response to care. Subjective reports from the patient regarding her care indicated improved mental acuity, sharper vocabulary, and a renewed passion for life. The patient went on to explain that since beginning chiropractic care, her health had actually improved, as she had seen no changes in balance, improvements in motor abilities, and a more clear mental state. Since the patient's ultimate goal was to relieve the symptomatology associated with Parkinson's disease, it was recommended she continue to be adjusted twice per week in order to ensure optimal functioning of the nervous system.

Discussion

Although Parkinson's is not a particularly common disease plaguing America today, an estimated seven to ten million people worldwide are living with Parkinson's disease, with many cases not yet detected.² The treatment for Parkinson's disease remains limited with little to no success rate at treating the disease itself. Since there is no known cure for PD, the medicinal and surgical treatment options available today are targeted at addressing the symptoms associated with the disease rather than the etiology.

The current medicinal treatments available today are Levodopa/Carbidopa, dopamine agonists, catechol-*O*-methyltransferase (COMT) inhibitors, monoamine oxidase type B (MAO-B) inhibitors, and anticholinergics.² Levodopa/Carbidopa, or a combination of the two, Sinemet, is the initial and often standard medication given to combat the symptoms associated with PD, however recent studies have discovered serious side effects related with prolonged use of these medications.

According to Jankovic and Stacy, as Parkinson's disease progresses, continued treatment using Levodopa or a similar derivative can cause up to 80% of patients to experience 'wearing-off' symptoms, dyskinesias and other motor complications. These Levodopa-associated problems may become disabling and profoundly effect quality of life.³² Medications commonly used to manage these symptoms include MAO-B inhibitors, COMT inhibitors, the NMDA receptor antagonist, Amantadine, and dopamine receptor agonists.

As an alternative, and at times an adjunct to medicinal treatment in those with advanced Parkinson's disease, surgical intervention in the form of deep brain stimulation is performed in order to lessen the motor symptoms that accompany PD. Unfortunately, in order to be a candidate for DBS, a certain level of cognitive ability must be present within the patient, thus limiting the population of PD sufferers who may be

eligible to receive this treatment. It has been shown that deep brain stimulation causes a reduction in motor symptoms (tremors), which occur in Parkinson's, consequently increasing one's functional status and quality of life.³³

Chiropractic and its role in Parkinson's disease

This is among the first of studies conducted on the efficacy of Activator Methods chiropractic adjustments in management of the symptoms associated with Parkinson's disease. Previous studies have been conducted on the role of upper cervical chiropractic care and chiropractic biophysics (CBP) in symptomatic improvement among those with PD, all demonstrating an overall improvement in symptomatology after receiving chiropractic care.²⁸⁻³¹

Although those who suffer from Parkinson's disease all experience similar symptoms, no two cases of PD are alike, given the complexity of the human brain and body. In reviewing the literature available, the words "chiropractic" and "Parkinson's disease" were entered into the PubMed and Index to Chiropractic Literature databases, with few articles returned. Of the articles found, the case studies determined to be relevant to this case study were reviewed.

The first case study found examined the effectiveness of chiropractic biophysics on improving subjective and objective complaints, posture and vertebral subluxation in a Parkinson's disease patient. The 67 year-old Caucasian male had been diagnosed with PD three years prior, as well as secondary psoriatic arthritis and lumbar radiculopathy when he presented into a private practice seeking chiropractic care. The initial examination included observation, testing of cervical and thoracolumbar spine ranges of motion, static and motion palpation, sensory and deep tendon reflexes, muscle testing, orthopedic and neurological examination, as well as cervical and lumbar radiographs.

Following the initial examination, the findings were assessed using CBP protocol and the patient's management plan was established. The patient underwent "corrective care" consisting of three visits per week for twelve weeks. The CBP corrective care consisted of mirror image spinal exercises, mirror image spinal adjustments, and mirror image spinal traction. Upon re-evaluation, increases in cervical and lumbar ranges of motion were reported. Gains in neck flexors, neck extensors, neck lateral flexors, trunk flexors and extensors, deep tendon reflexes and spinal alignment (particularly cervical lordosis) were also obtained.

The patient also conveyed improvements in activities of daily living, such as buttoning a shirt and tying shoes, as well as less difficulty swallowing and increased energy due to improved sleep quality. This study suggests that CBP may reduce the symptomatology found in patients with PD by improving spinal alignment and posture, while also aiding in improved activities of daily living.²⁸

The second study found addressed the symptomatic improvement in a patient with Parkinson's disease following upper cervical chiropractic care. A 66 year-old female, diagnosed with PD one-and-a-half years prior, presented at a National Upper Cervical Chiropractic Association (NUCCA)

clinic seeking chiropractic care. The patient's symptoms of a resting tremor in her left hand, fatigue, depression and rigidity in her extremities had been getting progressively worse since she fell when doing the Cha-Cha during a ballroom dancing function.

An initial examination was performed on the patient consisting of ranges of motion, postural analysis, functional leg length testing, thermography and sEMG. The findings of the physical examination warranted further x-ray assessment in order to obtain a three-dimensional study of the atlas to determine its exact positioning. Following x-ray analysis, the patient was adjusted using several light force maneuvers on the atlas until proper alignment was restored.

Following the adjustment, the patient stated she felt a warm flushing of her face. She compared the feeling she felt throughout her body to the sensation of muscular relaxation. After a rest period, the doctor determined her reaction to the adjustment (balanced leg lengths) warranted a post x-ray. Post x-rays revealed a correction in the alignment of her atlas to the skull and to her cervical spine that was objectively measurable, indicating horizontal planes of the atlas, skull and cervical spine were all restored to parallel.

Thermography and sEMG scans both showed improvement and the patient noted that since the adjustment all of the symptoms she had been previously experiencing had subsided. This study demonstrates the physiological benefits associated with precise correction of atlas subluxation, and warrants the need for further research investigating the role of upper cervical chiropractic care in treating the symptoms associated with Parkinson's disease.²⁹

The third case study published also addressed the reduction in symptoms related to Parkinson's disease affiliated with subluxation reduction following upper cervical chiropractic care. A 67 year-old female presented to a private NUCCA chiropractic practice seeking care for the symptoms of Parkinson's disease she was experiencing including weakness, tremors, scoliosis and rigidity, since she was diagnosed five years prior.

After a thorough physical examination, including supine leg length inequality, postural distortion, static/motion palpation, thermography and sEMG was conducted, radiographs were taken to measure the magnitude and direction of atlas misalignment. After six months of chiropractic care, including nineteen adjustments, the patient reported a 70% improvement in mobility and a significant decrease in the number of falls she experienced. The patient also noted improved ability to perform activities of daily living, including work, in addition to improvements in weakness, tremors and rigidity.

Objectively, improvements in radiographic measurements, paraspinal thermography and sEMG were also recorded. The results of this study suggests that correction of the atlas subluxation complex through orthogonal-based adjustments may improve symptoms and outcomes in patients with PD.³⁰ The last case study found discussed the use of upper cervical chiropractic care in managing a patient with Parkinson's disease and described a clinical picture of the disease. A 60

year-old male, diagnosed with Parkinson's disease seven years prior, presented to a private chiropractic practice seeking care for the symptoms he was experiencing including, resting tremors, rigidity, difficulty walking, slurring of speech and memory loss.

After a thorough physical examination including observation, thermography, cervical and lumbar spine ranges of motion, and evaluation of patient's symptoms using the Unified Parkinson's Disease Rating Scale (UPDRS), upper cervical radiographs were found in order to examine the integrity of the upper cervical spine. The patient underwent 9 months of care, receiving upper cervical adjustments at the C1 vertebral level, utilizing a knee-chest table.

By the second week of care, the patient reported gains in ranges of motion of his cervical spine, improved sleep, better energy levels and decreased stiffness in his body overall. In the weeks that followed, the patient reported decreased rigidity overall, enhanced hand and leg agility, continued increases in cervical ranges of motion, improvement in walking, and a dramatic advancement in balance allowing him to resume bike riding. Comparisons made between initial and final UPDRS evaluations showed an overall improvement of 43% in the patient's Parkinsonian symptoms after three months of care.

The results of this case study adds to the growing body of evidence that upper cervical chiropractic care may aid in the reduction of symptoms associated with Parkinson's disease when an upper cervical subluxation is found. Further investigation into upper cervical subluxation and injury as a possible or contributing factor to PD is warranted.³¹

Although individual case studies have been published regarding the reduction of symptoms associated with Parkinson's disease subsequent to chiropractic care, further research must be conducted regarding the restoration of proper spinal alignment and posture and its relation to the improvement in symptoms associated with Parkinson's disease.

Chiropractic is an art based on the removal of subluxation within the spine to allow for optimal neurological function. Chiropractors have often referred to spinal areas in need of manipulation as "spinal subluxations", based on a belief that there was impingement of the nerves at these sites produced by subluxation or approximation of adjacent vertebrae, where "subluxation" of the vertebrae is a slight deviation from its normal relation to adjacent vertebrae.³⁴ Due to subluxation, kinesiopathology, neuropathology, myopathology, histopathology and biochemical abnormalities can manifest within the body according to the Vertebral Subluxation Complex (VSC) model.³⁵

In regards to the patient discussed in this case, the patient presented with Parkinson's disease experiencing both essential and rest tremors along with subsequent neck pain and stiffness as well as lower back pain. Upon evaluation, it was evident the patient's spine had become biomechanically compromised due to the lack of range of motion in the cervical and lumbar spines as well and positive isolation tests performed using Activator protocol involving the pelvis, lumbar, thoracic and cervical vertebral segments.

The aforementioned abnormalities in the movement of the spine are referred to as kinesiopathology. Lantz describes kinesiopathology as abnormal motion, whether it be hypermobility, hypomobility or aberrant motion, and lack of motion within a joint leads to joint stiffness (loss of flexibility) with associated pain.³⁵ Kinesiopathology is often followed by degeneration of the joint and ultimate fusion by bony ankylosis.

As previously mentioned, degenerative joint disease was visible on the radiograph taken at the segments of C4/C5, C5/C6, and C6/C7 with decreased disc space and osteophytes on the anterior-superior and inferior endplates of C6 and the anterior-superior endplate of C7. The patient also had a reversal of the cervical curve, which may have led to the compromise of other soft tissue and osseous structures.

The neuropathologic component of the VSC involves many components including spinal nerves, dorsal root ganglion, neurotransmitters, trophic influences, etc. For quite some time, we have known that nerves release chemicals, called neurotransmitters, at their synaptic termini and that these substances elicit immediate and dramatic effects in the organs supplied by these nerves.

Chemical transmitters are involved in the perception of pain as well as light and sound, therefore knowledge of the chemical nature of nervous function forms the basis of our understanding of the function of the nervous system and must be included in any comprehensive model of subluxation.³⁵ Parkinson's disease involves the death of dopaminergic neurons within the Substantia Nigra, causing an obvious insufficiency in the dopamine neurotransmitter.¹ The motor symptoms which arise from a lack of dopamine can cause joint fixation, which has been demonstrated to lead to changes in sensory pathways, disuse of motor neurons and muscles, and thought to affect the central reflex pathways of the spinal cord.³⁶

As a result of motor deficits experienced with PD due to a lack of dopamine, muscular imbalances occur due to the inability to execute smooth, controlled movements causing hypo- and hypertonicity as well as eventual muscle atrophy in later stages of the disease. As a result of these muscular changes, joint immobilization/fixation may occur giving way to the myopathology component of VSC. Joint fixation, along with the decrease in motor function seen with Parkinson's disease, may contribute to the causal factors giving way to muscle atrophy. Muscle atrophy, either secondary to joint immobilization or due to disuse as a result of a dopamine deficit, may lead to joint degeneration.³⁷

The hypertonic musculature seen through palpation as well as through static surface electromyography, can be attributed to both joint fixation detected in the patient's spine as well as a dopamine deficiency, causing muscular imbalances due to the motor symptoms associated with Parkinson's disease. An improvement in hypertonicity of the paraspinal muscles, as evidenced by sEMG scans and increased ranges of motion in the cervical and lumbar spine, in conjunction with subjective reports given by the patient stating decreased muscle tremors and increased motion in her cervical spine, support the notion that chiropractic care aids in the reduction of symptoms

associated with Parkinson's disease.

In addition, both chiropractic adjustments and the postural exercises performed by the patient allowed for proper motion to be restored within the spine at individual vertebral levels. Treating both the kinesiopathology and myopathology components of the VSC allowed for the nervous system to function to the best of its ability given the neurological state of the patient, allowing for a decrease in hand tremors, increase ranges of motion, and a reduction in the over-all pain levels of the patient as a result of the dysfunction occurring within the spine.

Conclusion

There is currently no known cure for Parkinson's disease as treatment options available today deal primarily with treating the symptoms rather than the cause of the pathology. Past studies have shown the efficacy of chiropractic biophysics and upper cervical chiropractic adjustments on decreasing the symptomology experienced by those with PD. This case report adds to the growing body of evidence that chiropractic care can be used as a means of alternative treatment in lessening the side effects experienced by Parkinson's disease patients. It is imperative that the chiropractic profession continues to research this relationship utilizing well-designed clinical trials and scientific-based research to study the mechanisms by which chiropractic is beneficial as a method of treatment for Parkinson's disease symptoms.

References

1. Rao SS, Hoffman LA, Shakil A. Parkinson's disease: diagnosis and treatment. *Am Fam Physician* 2006 Dec 15;74(12):2046-54.
2. Parkinson's Disease Foundation, Inc. http://www.pdf.org/en/parkinson_statistics.
3. Bergman H, Deuschl G. Pathophysiology of Parkinson's disease: from clinical neurology to basic neuroscience and back. *Mov Disord* 2002;17 Suppl 3:S28-40.
4. Daniels C. Clinical brief: Classification of essential and Parkinson's tremors. *Top Integr Health Care* 2012;3(1):Online access only 7 p.
5. Deuschl G, Bain P, Brin M. Consensus statement of the Movement Disorder Society on tremor. *Ad Hoc Scientific Committee. Mov Disord* 1998;13 Suppl 3:S2-S23.
6. Elble R. Diagnostic criteria for essential tremor and differential diagnosis. *Neurology* 2000;54:S2-S6.
7. Stack E, Ashburn A, Jupp K. Postural instability during reaching tasks in Parkinson's disease. *Physiother Res Int* 2005;10:146-153.
8. Varanese S, Birnbaum Z, Rossi R, DiRocco A. Treatment of advanced Parkinson's disease. *Parkinsons Dis* 2010;2010:480260.
9. Gnädinger M, Mellinghoff HU, Kaelin-Lang A. Parkinson's disease and the bones. *Swiss Med Wkly* 2011;141:w13154.
10. Vaugoyeau M, Hakam H, Azulay JP. Proprioceptive impairment and postural orientation control in Parkinson's disease. *Hum Mov Sci* 2011 Apr;30(2):405-14.
11. Schenkman ML, Clark K, Xie T, Kuchibhatla M, Shinberg M, Ray L. Spinal movement and performance of a standing reach task in participants with and without Parkinson's disease. *Phys Ther* 2001 Aug;81(8):1400-11.
12. Vaugoyeau M, Viel S, Assaiante C, Amblard B, Azulay JP. Impaired vertical postural control and proprioceptive integration deficits in Parkinson's disease. *Neurosci* 2007 May;146(2):852-863.
13. Appleman E, Stavitsky K, Cronin-Golomb A. Relation of subjective quality of life to motor symptom profile in Parkinson's disease. *Parkinsons Dis* 2011 May;2011:472830.
14. Pringle RK. Intra-instrument reliability of 4 goniometers. *J Chiropr Med* 2003 Summer;2(3):91-95.
15. Cooperstein R, Morschhauser E, Lisi A, Nick TG. Validity of compressive leg checking in measuring artificial leg-length inequality. *J Manipulative Physiol Ther* 2003 Nov-Dec;26(9):557-66.
16. Deboer KF, Harmon RO Jr, Savoie S, Tuttle CD. Inter- and intra-examiner reliability of leg length differential measurement: a preliminary study. *J Manipulative Physiol Ther* 1983 Jun;6(2):61-6.
17. Uematsu S, Edwin DH, Jankel WR, Kozikowski J, Trattner M. Quantification of thermal asymmetry. Part 1: Normal values and reproducibility. *J Neurosurg* 1988 Oct;69(4):552-5.
18. Gentempo P, Kent C, Hightower B, Minicozzi SJ. Normative data for paraspinal muscle activity associated with vertebral subluxation: a review. *J Vert Sublux Res* 1997;1(3):15-22.
19. Kent C. Surface electromyography in the assessment of changes in paraspinal muscle activity associated with vertebral subluxation: a review. *J Vert Sublux Res* 1997;1(3):15-22.
20. Gatterman MI, Hansen DT. Development of chiropractic nomenclature through consensus. *J Manipulative Physiol Ther* 1994 Jun;17(5):302-9.
21. Fuhr AW, Menke JM. Status of activator methods chiropractic technique, theory, and practice. *J Manipulative Physiol Ther* 2005;28(2):e1-e20.
22. Slosberg M. Effects of altered afferent articular input on sensation, proprioception, muscle tone and sympathetic reflex responses. *J Manipulative Physiol Ther* 1988 Oct;11(5):400-8.
23. Slosberg M. Spinal learning: Central modulation of pain processing and long-term alteration of interneuronal excitability as a result of nociceptive peripheral input. *J Manipulative Physiol Ther* 1990 July-Aug;13(6):326-36.
24. Fuhr AW, Colloca CJ. Evaluation and management of common clinical syndromes utilizing Activator Methods Chiropractic Technique. *DC Tracts* 1998;10:3-8.
25. Fuhr AW, Osterbauer PJ. Inter-examiner reliability of relative leg-length evaluations in the prone, extended position. *Chiropr Tech* 1989;2:13-8.
26. Maigne JY, Guillon F. Highlighting of intervertebral movements and variations of intradiskal pressure during lumbar spine manipulation: a feasibility study. *J Manipulative Physiol Ther* 2000 Oct;23(8):531-5.
27. Nathan M, Keller TS. Measurement and analysis of the in vivo posteroanterior impulse response of the human thoracolumbar spine: a feasibility study. *J Manipulative Physiol Ther* 1994 Sep;17(7):431-41.

28. Shapiro DA, Pickrell NE. Chiropractic care of a patient with Parkinson's disease utilizing Chiropractic Biophysics: a case study. *Ann Vert Sublux Res* 2012 Spr;(2012:2):Online access only p 31-40.
29. Bello R. Symptomatic improvement in a patient with Parkinson's disease subsequent to upper cervical chiropractic care: a case study. *J Upper Cervical Chiropr Res* 2011 Spr;1(2):Online access only p 31-38.
30. Chung J, Brown J. Reduction in symptoms relation to Parkinson's disease concomitant with subluxation reduction following upper cervical chiropractic care. *J Upper Cervical Chiropr Res* 2011 Win;1(1):Online access only p 18-21.
31. Elster E. Upper cervical chiropractic management of a patient with Parkinson's disease: a case report. *J Manipulative Physiol Ther* 2000 Oct;23(8):573-577.
32. Jankovic J, Stacy M. Medical management of Levodopa-associated motor complications in patients with Parkinson's disease. *CNS Drugs* 2007;21(8):677-92.
33. Massano J, Garrett C. Deep brain stimulation and cognitive decline in Parkinson's disease: a clinical review. *Front Neurol* 2012;3:66.
34. Walker BF, Buchbinder R. Most commonly used methods of detecting spinal subluxation and the preferred term for its description: a survey of chiropractors in Victoria, Australia. *J Manipulative Physiol Ther* 1998 Jul-Aug;21(6):428-9.
35. Lantz C. The vertebral subluxation complex part 1: an introduction to the model and kinesiological component. *Chiropr Res J* 1989;1(3):23-36.
36. Sharpless SK, Groves P, Cobb S, et al. Neurophysiology of nerve compression and joint fixation. *The Fifth Annual Biomechanics Conference of the Spine, Biomechanics Laboratory, University of Colorado, Boulder, Colorado, December 1974, p. 219-277.*
37. Lantz C. The vertebral subluxation complex part 2: the neuropathological and myopathological components. *Chiropr Res J* 1990;1(4):19-38.

Figures

Figure 1. Initial thermography and sEMG scans

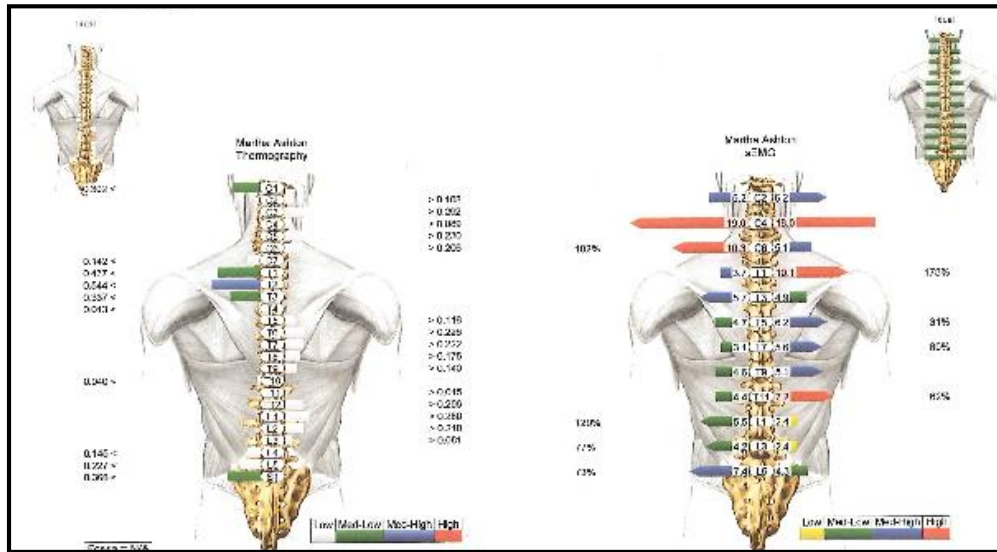


Figure 2. Initial Lateral Cervical Radiograph

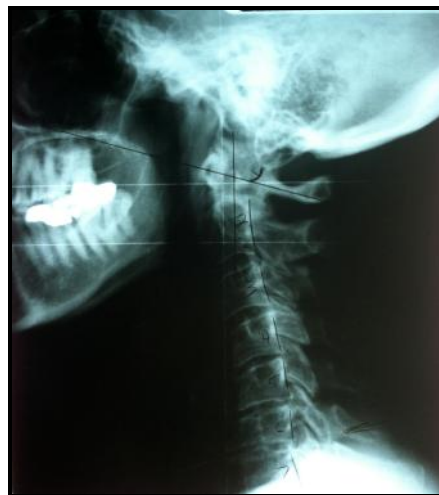

Figure 3 & 4. Two month follow-up (top) & Four month follow-up (bottom) Thermography and sEMG scans

